



# Cadaveric ichthyofauna of the Madeira River in the Amazon basin: the myth of man-eating piranhas

Murilo Sérgio Valente-Aguiar<sup>1,2</sup> · Ana Cecília Falcão<sup>3</sup> · Teresa Magalhães<sup>1,4</sup> · Ricardo Jorge Dinis-Oliveira<sup>1,4,5</sup>

Accepted: 13 January 2020

© Springer Science+Business Media, LLC, part of Springer Nature 2020

## Abstract

Drowned bodies rescued from the rivers of the Amazon basin exhibit several artefacts caused by the actions of the cadaveric ichthyofauna, namely, the “candiru”. This study aims to review and discuss the fish species responsible for the largest number of attacks on bodies in the Madeira River (Porto Velho - Rondônia, Brazil), to describe the feeding strategies and types of lesions caused by each species, and to demystify the myth of the “man-eating piranhas”. To the best of our knowledge, this study is the first that aims to provide a systematic analysis of cadaveric ichthyofauna and forensic findings in this region.

**Keywords** Cadaveric ichthyofauna · Piranha · *Cetopsis candiru* · *Cetopsis coecutiens* · *Calophysus macropterus* · *Serrasalmus rhombeus* · *Pygocentrus nattereri*

## Introduction

The rivers of the Brazilian Amazon basin contain an estimated 2411 different species of fish [1, 2]. Approximately 1165 species live in the Madeira River, a river characterized by muddy waters that bathes the city of Porto Velho, capital of the State of Rondônia [3]. In the popular culture of the Amazon natives, some of these fish, particularly the “candiru” and piranhas, are feared and believed as capable of devouring human bodies or

entering the urethra when the individual, without clothes, urinates in the river [4, 5]. “Candiru” is a generic umbrella term for various species of fish belonging to the Cetopsidae, Pimelodidae and Trichomycteridae families, and these species are usually named catfish due to their barbels. Piranhas, members of the Serrasalminidae family, are opportunistic carnivorous freshwater fish that inhabit South American rivers. They attained the reputation of human devourers from the American president Theodore Roosevelt, who described the scientific expedition that occurred between 1913 and 1914 in his book *Through the Brazilian Wildernesses*, which was published in 1914 [6]. In that document, the author reported that piranhas could shatter or devour any wounded man or animal, and blood in the water would excite these fish to madness [6]. After the box office success of the film “Shark” in 1975, Hollywood film studies produced the film “Piranha” in 1978, which was inspired by Roosevelt’s report of the piranha’s attack. This movie and several other film productions contributed even more to the false legend of “man-eating piranhas” [7]. Therefore, piranhas have attained this fearsome reputation, despite the absence of reliable reports of people who have been attacked and killed by these fish [7, 8].

This study aims to review and discuss the fish species responsible for the largest number of attacks on bodies in the region of Porto Velho (Rondônia), to describe the feeding strategies and types of artefacts caused by each species, and to demystify the myth of “man-eating piranhas”. The literature does not contain a systematic description of this cadaveric

✉ Murilo Sérgio Valente-Aguiar  
up201707626@med.up.pt

✉ Ricardo Jorge Dinis-Oliveira  
ricardinis@med.up.pt

<sup>1</sup> Department of Public Health and Forensic Sciences, and Medical Education, Faculty of Medicine, University of Porto, Alameda Prof. Hemâni Monteiro, 4200-319 Porto, Portugal

<sup>2</sup> Legal Medical Institute of Porto Velho, Civil Police of the State of Rondônia, Porto Velho, Brazil

<sup>3</sup> Integrated Faculties of Aparício de Carvalho, Porto Velho, B State of Rondônia, Brazil

<sup>4</sup> IINFACTS - Institute of Research and Advanced Training in Health Sciences and Technologies, Department of Sciences, University Institute of Health Sciences (IUCS), CESPU, CRL, Gandra, Portugal

<sup>5</sup> UCIBIO-REQUIMTE, Laboratory of Toxicology, Department of Biological Sciences, Faculty of Pharmacy, University of Porto, Porto, Portugal

ichthyofauna and related artefacts. The autoptic artefacts are somewhat characteristic of each species that fed on bodies, enabling us to potentially identify the implicated fish species.

## Case reports

A retrospective analysis of 101 forensic autopsy reports of drowning cases from the Institute of Legal Medicine of Porto Velho was conducted between January 2014 and December 2019. All cases of ichthyofauna attacks occurred in natural water reservoirs, accounting for 21% of drowning-related autopsies. Fish from 2 families belonging to 5 distinct species were identified as responsible for the autoptic findings, and illustrative cases are presented (Table 1).

The fish from the Cetopsidae family (Figs. 1 and 2) present a completely smooth body that is devoid of bony plates or thorns and nasal barbels. The head has a globular appearance resulting from the robust cephalic musculature, which covers part or all of the roof of the skull, ensuring the powerful operation of the specialized dental arsenal and an efficient cutting apparatus; the edges of the incisiform teeth are aligned, forming an almost continuous sharp surface on the former [9]. Figure 1 presents a case of a 16-year-old boy who tried to swim across the river. He was surprised by the velocity and flow of the water, and eventually tired and drowned. His body was recovered eight hours later. Figure 2 presents a case of a 65-year-old man who, after noticing that his canoe was drifting in the middle of the river, tried to retrieve it with the help of his friend. It was raining and windy, and the canoe had

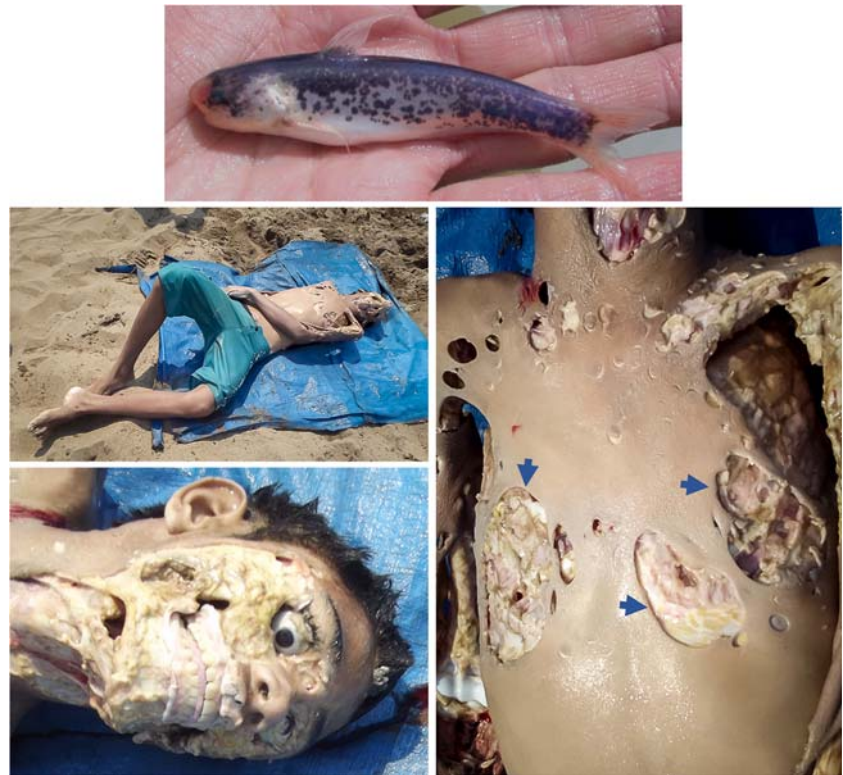drifted a long way. His friend returned to the riverbank where he could see the victim was drowning. The cadaver was recovered 14 h later. The recorded damage to the bodies was compatible with the actions of fish from the genus *Cetopsis*, which are widely distributed in the Amazon Basin, namely, in the Madeira River and along the banks of the city of Porto Velho. *Cetopsis candiru* (Fig. 1) and *Cetopsis coecutiens* (Fig. 2) are particularly abundant in these areas. The length of *Cetopsis candiru* varies from 1.8 to 26.3 cm and it attacks dead bodies in shoals, devouring them from the inside out after making entry holes in the body [9, 10]. *Cetopsis coecutiens* has a greater geographical family distribution. Its length ranges from 2.3 to 26.4 cm and it participates in feeding frenzies along with *Cetopsis candiru*, but does not usually remain inside the body [9–11]. Both cases exhibited damage with a characteristic concentric pattern.

The family Pimelodidae includes members of an almost archetypal model of a catfish (Figs. 3 and 4). These animals have a naked body (without external bony plates) with a relatively large adipose fin and three pairs of long barbels (one jaw pair and two mentonians). The color of the body can range from a uniform grey to fairly elaborate patterns of stripes or dark and light spots [9, 10]. A 29-year-old man was fishing when his canoe turned over and his body submerged. The body was recovered 48 h later by riverbank inhabitants. *Calophysus macropterus* (also known as piracatinga, vulture catfish, or zamurito) were recovered from under his clothes, probably because they are the most common fish species of the cadaverous ichthyofauna in the Madeira River (Fig. 3). A 16-year-old woman who was 5 months pregnant committed suicide by drowning as the baby's father had refused

**Table 1** General characteristics of the Cetopsidae and Pimelodidae families

SPECIES AND FEATURES		SPECIES AND FEATURES	
<b>Cetopsidae</b>	<ul style="list-style-type: none"> <li>• Known as “whale catfishes” and “candiru”</li> <li>• A completely smooth body with 3 pairs of barbels located around the mouth, but without nasal barbels, bony plates or thorns</li> <li>• The head has a globular appearance resulting from the robust cephalic musculature</li> <li>• Small- to medium-sized catfishes and a maximum length of approximately 26 cm</li> <li>• Specialized dental arsenal and an efficient cutting apparatus</li> <li>• The edges of the incisiform teeth are aligned, forming an almost continuous sharp surface on the forme</li> </ul>	<b><i>Cetopsis candiru</i></b>	<ul style="list-style-type: none"> <li>• The length varies from 1.8-26.3 cm</li> <li>• It is widely distributed in the Amazon basin, namely, in the Madeira River and in the banks along the city of Porto Velho</li> <li>• Voracious feeding habits</li> <li>• Devours corpses in large numbers from the inside out</li> </ul>
		<b><i>Cetopsis coecutiens</i></b>	<ul style="list-style-type: none"> <li>• Length ranges from 2.3-26.4 cm</li> <li>• It is widely distributed in the Amazon basin, namely, in the Madeira River and along the banks of the city of Porto Velho</li> <li>• Voracious feeding habits</li> <li>• Participates in the food frenzy along with <i>Cetopsis candiru</i>, but does not remain inside the corpse</li> </ul>
<b>Pimelodidae</b>	<ul style="list-style-type: none"> <li>• Naked body (without external bony plates) with a relatively large adipose fin</li> <li>• Three pairs of long barbels (one jaw and two mentonians)</li> <li>• The colour of the body can range from a uniform grey to fairly elaborate patterns of stripes and dark and light spots</li> </ul>	<b><i>Calophysus macropterus</i></b>	<ul style="list-style-type: none"> <li>• Known as the piracatinga or water buzzard, the latter name is a clear reference to the voracity of these fish, which consume various types of food and are strong scavengers (consuming carcasses of dead animals)</li> <li>• The length varies from 19-71 cm</li> <li>• The most common fish species among the cadaverous ichthyofauna in the Madeira River</li> </ul>

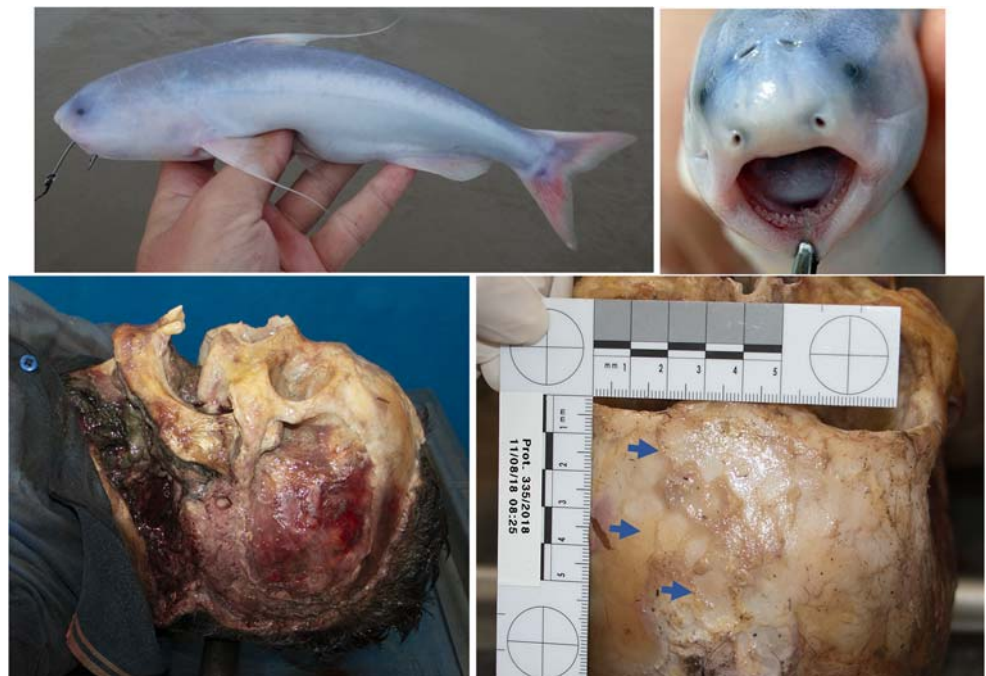**Fig. 1** Forensic artefacts caused by the *Cetopsis* genus in a cadaver, most likely due to *Cetopsis candiru*. Arrows highlight the outer surface artefacts used by fish as the entrance to the carcass



to acknowledge the child, presumably because he was a married man (Fig. 4). The victim was recovered 17 h after drowning. The skeletonization of the body along with the preservation of the cartilage, eyeballs, scalp and the extremities of the limbs suggested the feeding actions of *Calophysus macropterus*. The length of this species ranges from 19 to 71 cm and it has a wide

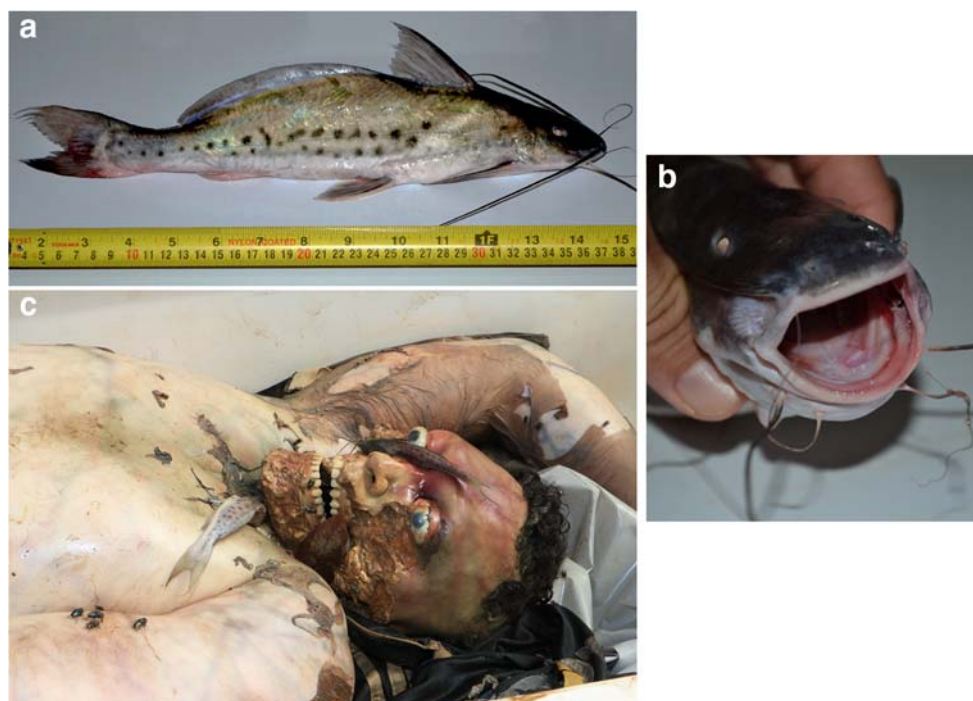
distribution in the basins of the Amazonas and Orinoco rivers [9, 10, 12]. It is known by the common names of “piracatinga”, “pintadinho”, “vulture catfish”, “zamuraito” or “water buzzard”, the latter of which is a clear reference to the voracity of these fish, which consume various types of food, such as the carcasses of dead animals [9, 10].

**Fig. 2** Forensic artefacts caused by the *Cetopsis* genus in a cadaver, most likely due to *Cetopsis coecutiens*. Arrows highlight the circular perforating punch artefacts caused by the rotating movement of the fish when biting





**Fig. 3** Lateral view of *Calophysus macropterus* with a near-maximum adult size and barbels protruding from the mouth that serve as taste sensors (a). The mouth has two rows of teeth in the premaxilla (b). Forensic artefacts caused *Calophysus macropterus* and fish recovered from under clothing (c)

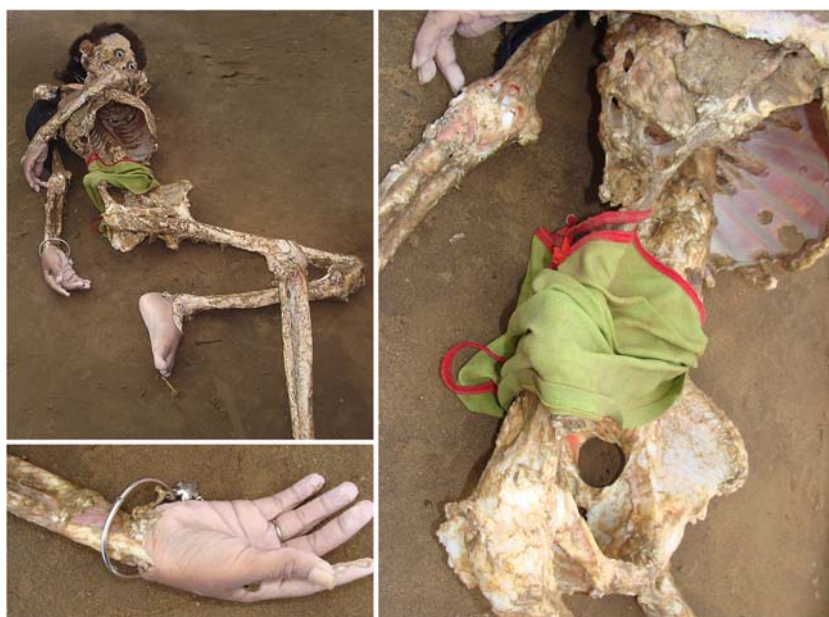

## Discussion

Many victims of drowning in the Amazon region, particularly in the river, are not recovered, either because of the vastness of the river or because they are devoured by carnivorous or scavenging fish. Members of the Cetopsidae family are known to riverside populations as carrion-eating fish, and attacks on bodies found submerged in the waters of the Madeira River are attributed to them. They have ravenous eating habits and attack not only carrion but also fish caught on hooks and in

waiting nets [9], differing only in their attack and feeding strategies. *Cetopsis candiru* devours tissues using a swift rotating movement that is similar to a drilling machine. The fish creates one to a few small holes (Fig. 1) in the outer surface to enter the body, which is often devoured from the inside out. It can remain inside the body for a long time, resulting in a feeding frenzy that can attract tens to hundreds of individuals that sometimes completely fill the interior of the cavities with a swirling mass of vermiform fish [9]. In contrast, *Cetopsis coecutiens* usually performs rapid attacks on prey,

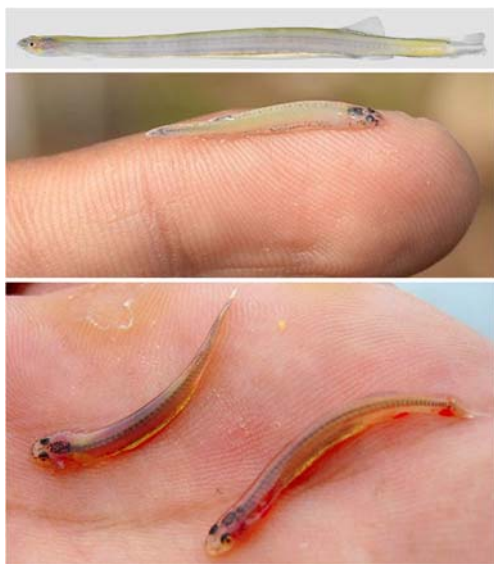**Fig. 4** Forensic artefacts in a cadaver caused by *Calophysus macropterus*. Skeletonization of the body and preservation of the cartilage, the eyeballs, the scalp and the extremities of the limbs were observed



withdrawing immediately with the removed tissue and then returning for another attack, but does not remain inside the body [9]. This action is compatible with the forensic findings registered in the case presented in Fig. 2.

*Calophysus macropterus* is also present in the waters of the Madeira River and contributes to the destruction of bodies. Individuals of this species are more likely to be found under the clothes of bodies during forensic autopsies. These fish promote the skeletonization of the body, with the preservation of the cartilage, the eyeballs, the scalp and the extremities of the limbs, and can consume all of the muscles and viscera of an 80 kg dead human body in half an hour. These fish are extremely voracious; they feed in shoals and have territorial habits. This has led them to become known as “water vultures” [13]. An experiment performed with a small piece of meat and bones submerged in the river resulted in almost immediate consumption (data not shown) and comparable findings to the data presented in Fig. 4. More recently, piracatinga was proposed as a useful tool for locating the remains of drowning victims in the Amazon, particularly when combined with the analysis of DNA samples from relatives of the deceased [14].

Other species have been anecdotally associated with devouring cadavers, but most reports failed to provide scientific evidence of their involvement. *Vandellia cirrhosa* (Fig. 5) of the Trichomycteridae family is also called “candiru” by the Amazon natives and it is one of the best-known fish species in Brazil [15, 16]. It is a small and transparent fish that is quite difficult to spot in the turbid waters of its home; it is approximately 2.5–6 cm long and is known by the common name “vampire fish” as they are hematophagous and feed on blood from the gills of larger fish gills [4, 15]. An




**Fig. 5** *Vandellia cirrhosa*, a hematophagous fish known as “vampire fish”

unconfirmed theory states that these fish are attracted by the ammonia eliminated in the water during fish breathing, and therefore, they enter the urethra of people who bathe naked and urinate into the water. Researchers have not yet proven that the fish are truly urinophilic. The World Encyclopedia of Animals provides a different explanation: the fish enters the urethra accidentally because its instinct is to swim against the stream of water flowing out of the gill cavity of the larger fish that is generated by the movement of the opercula and is confused by the flow of urine into the water [17]. Some indigenous tribes in endemic areas have developed interesting methods to protect themselves from the attack of *Vandellia cirrhosa*. The “inobá”, used by the Indians of the Baróro ethnic group, is a penis protector made with dry leaves from a palm tree intertwined in a wraparound envelope at the waist. In turn, women use a device called an “uluri” that is built with bark to protect the genitals [17, 18]. When the fish enters the urethra, the natives use jenipapo juice (*Genipa americana*), which is offered as a drink and injected into the urethra. Because it is rich in citric acid, this juice dissolves the calcium present in the small spines in the opercula that are used to attach to the parasite’s gills, and thus the fish is easily removed from the urethra [4]. Rare accidents have been documented with the penetration of fish into the urethra, vagina, or anus of people who bathe naked in Amazonian rivers [5, 19], but these species are not involved in wildlife attacks on submerged corpses.

Finally, the responsibility of piranhas for our findings observed in cadavers must be demystified and questioned. Although these opportunistic carnivores are present in the Madeira River, they are rarely seen, and many fishermen declare that they have never caught piranhas. The piranhas reported in the Madeira River belong to the species of *Serrasalmus rhombeus* (Fig. 6A) or *Pygocentrus nattereri* (Fig. 6B). *Serrasalmus rhombeus* (i.e. the redeye piranha or the black piranha) is a fish of the piranha family Serrasalminidae found in South America in the Amazon. *Pygocentrus nattereri* (i.e. the red-bellied piranha or red piranha) is a species of piranha native to South America, namely, the Madeira River [12]. Both species usually feed on other smaller fish, aquatic insect larvae and crustaceans such as shrimps. These species rarely attack cadavers, and when they do, the attack is mainly because the animals feel threatened or hungry due to the reduced amount of food available when the river level drops during the dry season [20]. Piranha attacks on living humans are limited to single bites that are almost always located on the lower (i.e. feet) and upper (i.e. hands) extremities, particularly during spawning in the reproductive season to protect the fry. The bite typically consists of a single circular wound resembling a volcano crater [20, 21]. Indeed, the teeth of the piranhas are like blades, sharp and thin, allowing them to create a quick puncture followed by an incisive cut [20, 22].





**Fig. 6** *Serrasalmus rhombeus* (A) and *Pygocentrus nattereri* (B) are the most common species of piranhas indigenous to the Madeira River

## Conclusions

In conclusion, an extensive group of fish from the Amazon basin are omnivorous and eventually feed on carcasses. Fish from two distinct families (Cetopsidae and Pimelodidae) were identified as being responsible for the necrophagous actions on submerged bodies in the waters of the Madeira River. *Serrasalmus rhombeus*, *Pygocentrus nattereri* and the *Vandellia cirrhosa* do not participate in cases of wildlife attacks on submerged bodies. Our findings also reveal that although characteristic damage patterns were observed and linked to a specific fish family, further systematic forensic studies are needed to characterize artefacts caused by cadaveric ichthyofauna.

## Key points

1. A retrospective analysis of the 101 forensic autopsy reports drowning cases was performed.
2. Five species of fish from 2 families were identified as responsible for autopsy findings of predation in drowned bodies.
3. “Candiru” are responsible for several artifacts in drowned bodies.
4. “Candiru” and not piranhas are the species of fish in the Madeira River responsible for devouring bodies.

5. *Serrasalmus rhombeus*, *Pygocentrus nattereri* and *Vandellia cirrhosa* are not involved in attacks or predation.

**Acknowledgements** This work was supported by grants from CESP (TramTap-CESPU-2016, Chronic-TramTap\_CESPU\_2017 and TraTapMDMA-CESPU-2018). The authors are also thankful to Professor Carolina Dória of the Federal de Rondônia University.

## References

1. Reis RE, Albert JS, Di Dario F, Mincarone MM, Petry P, Rocha LA. Fish biodiversity and conservation in South America. *J Fish Biol.* 2016;89:12–47.
2. Oberdorff T, Dias MS, Jezequel C, Albert JS, Arantes CC, Bigorne R, et al. Unexpected fish diversity gradients in the Amazon basin. *Sci Adv.* 2019;5:eaav8681.
3. Melo BF, Oliveira C. Three new species of Curimatopsis (Characiformes: Curimatidae) from the Amazon basin. *J Fish Biol.* 2017;91:528–44.
4. Arango Toro OJ, Arbelaez Arango S, Franco ME. *Vandellia cirrhosa*, poorly known urologic parasite. *Actas Urol Esp.* 2001;25:325–6.
5. Bauer IL. Candiru—a little fish with bad habits: need travel health professionals worry? A review. *J Travel Med.* 2013;20:119–24.
6. Roosevelt T. Through the Brazilian wilderness. New York: Skyhorse Publishing; 1999.
7. Sazima I, de Andrade Guimarães S. Scavenging on human corpses as a source for stories about man-eating piranhas. *Environ Biol Fish.* 1987;20:75–7.
8. Haddad V Jr, Sazima I. Piranha attacks in dammed streams used for human recreation in the state of Sao Paulo, Brazil. *Rev Soc Bras Med Trop.* 2010;43:596–8.
9. Queiroz LJD, Torrente-Vilara G, Ohara WM, Pires THDS, Zuanon J, Doria CRDC. Peixes do rio Madeira. Santo Antônio Energia: São Paulo; 2013.
10. Vari RP, Ferraris Jr CJ, Pinna MCCd. The Neotropical whale catfishes (Siluriformes: Cetopsidae: Cetopsinae), a revisionary study. *Neotropical Ichthyology.* 2005;3:127–238.
11. Abrahao VP, de Pinna MCC. *Cetopsis varii*, a new species of whale catfish (Siluriformes: Cetopsidae) from the Meta Basin, Colombia. *J Fish Biol.* 2018;93:110–8.
12. CRdC D, Ruffino ML, Hijazi NC, RLd C. A pesca comercial na bacia do rio Madeira no estado de Rondônia, Amazônia brasileira. *Acta Amazon.* 2012;42:29–40.
13. Pérez A, Fabrè NN. Seasonal growth and life history of the catfish *Calophysus macropterus* (Lichtenstein, 1819) (Siluriformes: Pimelodidae) from the Amazon floodplain. *J Appl Ichthyol.* 2009;25:343–9.
14. Jennings Simoes EL. Forensic use of the Piracatinga fish (*Calophysus macropterus*) to locate and identify human remains retrieved from the Amazon river. *J Forensic Sci.* 2018;63:1587–91.
15. Mehlhorn H. Encyclopedia of Parasitology. Berlin, Heidelberg: Springer Berlin Heidelberg; 2008. p. 1550.
16. Fatovic-Ferencic S, Durigl MA, Repanic-Braun M. Two unconventional testimonies of urolithiasis in the 18th century on the 1600th anniversary of St. Liborius' death (397-1997). *Scand J Urol Nephrol.* 1998;32:245–9.
17. Breault JL. Candirú: Amazonian parasitic catfish. *J Wilderness Med.* 1991;2:304–12.
18. Moran ME, Charlatans, quacks, Stephens J. Urolithiasis: A comprehensive history. New York: Springer; 2014. p. 67–83.

19. Herman JR. Candiru: urinophilic catfish. Its gift to urology. *Urology*. 1973;1:265–7.
20. Haddad V Jr, Sazima I. Piranha attacks on humans in Southeast Brazil: epidemiology, natural history, and clinical treatment, with description of a bite outbreak. *Wilderness Environ Med*. 2003;14: 249–54.
21. Berkowitz T, Goldsmith MP. An unexpected fish bite. *Pediatr Emerg Care*. 2017;33:258–9.
22. Grubich JR, Huskey S, Crofts S, Orti G, Porto J. Mega-bites: extreme jaw forces of living and extinct piranhas (Serrasalminidae). *Sci Rep*. 2012;2:1009.

**Publisher's note** Springer Nature remains neutral with regard to jurisdictional claims in published maps and institutional affiliations.